



Published By:
Surgical Residency Program
Universitas Syiah Kuala

Sinonasal Inverted Papilloma Extirpation by Endoscopic Approach: a Case Report



Teuku Husni T.R^{1*}, Ridha Chaharsyah Mulya²

ABSTRACT

Introduction: Inverted papilloma is a benign tumor that generally arises from the lateral wall of the nasal cavity and mostly grows on the middle meatus. The incidence is rarely found in the ear, throat, nose, throat, head and neck, around 0.5% -4% of all nasal and paranasal sinus tumors. The etiology of inverted papilloma remains unknown. Clinical features of inverted papilloma are unilateral nasal obstruction, rhinorrhea, epistaxis, anosmia, tinnitus and other symptoms. The diagnostic examination are histopathological examinations, CT scans and MRI. Histopathology is the gold standard in diagnosing of inverted papilloma. Management of inverted papilloma is carried out with surgical approach including lateral rhinotomy, maxillectomy, degloving, and non-invasive surgery via endoscopy depend to the krouse classification.

Case description: A 44 year-old female patient diagnosed with inverted papilloma was reported. The patient complained of progressive right nasal obstruction appeared two years ago that turn into total obstruction and rhinorrhea in the last 6 months. A biopsy was done with the result of inverted papilloma. CT scan of the paranasal sinuses showed a mass filling the right nasal cavity, right maxillary sinus and right ethmoid sinus. Patient was diagnosed with sinonasal inverted papilloma with krouse 2 classification based on clinical examination, radiological finding and preoperative endoscopy. Patient was treated with sinonasal inverted papilloma extirpation via endoscopic approach.

Conclusion: Inverted papilloma is a benign tumor of the nasal and paranasal sinuses, and biopsy is the gold standard for diagnostic tests. At the same time, the main treatment is done by surgical approach depend on the krouse classification.

Keywords: benign mass, endoscopic approach, inverted papilloma.

Cite This Article: Husni, T.R.T., Mulya, R.C. 2022. Sinonasal Inverted Papilloma Extirpation by Endoscopic Approach: a Case Report. *Journal of International Surgery and Clinical Medicine* 2(2): 36-39. DOI : 10.51559/jiscm.v2i2.30

¹Ear, Nose, Throat, Head, and Neck Surgery Department, Faculty of Medicine, Universitas Syiah Kuala-Zainoel Abidin General Hospital, Banda Aceh, Indonesia;

²Ear, Nose, Throat, Head, and Neck Surgery Residency Program, Faculty of Medicine, Universitas Syiah Kuala-Zainoel Abidin General Hospital, Banda Aceh, Indonesia;

*Corresponding to:

Teuku Husni T.R.;
Ear, Nose, Throat, Head, and Neck Surgery Department, Faculty of Medicine, Universitas Syiah Kuala-Zainoel Abidin General Hospital, Banda Aceh, Indonesia;
teukuhusnitr@unsyiah.ac.id

Received: 2022-10-30

Accepted: 2022-12-08

Published: 2022-12-27

INTRODUCTION

Inverted papilloma is a benign tumor of nasal cavity which is commonly originated from the lateral wall of nasal cavity and middle meatus and rarely found on nasal septum. It consisted of pseudostratified ciliated columnar epithelium on the sinonasal region. Sinonasal tumor grew locally and aggressively with high recurrence rate. This tumor can develop into malignancy so that the preferred treatment option is total tissue resection.¹⁻³

The incidence rate of inverted papilloma was low on ear, nose, throat, head and neck region which is between 0,5-4% of the whole nasal and paranasal sinus tumor. Clinically, the morphology resembles to polyp but the consistency is denser than nasal polyp. Inverted papilloma tends to be found unilaterally. The incidence is higher on men compared to women with the comparison of 3:1. Patient was mainly aged between 50-70 years old with the average of 53 years old.^{1,2,4}

The exact cause of inverted papilloma remains unknown. Several theories have been proposed including allergy, chronic inflammation, and carcinogenic process related to papilloma virus infection. Extrinsic factors such as carcinogenic air pollution and industrial waste were assumed to be the cause. A number of virus is suspected to be the etiology of this neoplastic lesion due to its tendency to form papilloma on body organs. HPV-11, HPV-6, HPV-16, and HPV-18 had been identified on inverted papilloma.^{1,2,5}

Inverted papilloma is frequently unilateral causing unilateral nasal obstruction. Other probable symptoms include rhinorrhea, epistaxis, anosmia, tinnitus. The triad of main clinical manifestations of tumor are tendency to relapse, ability to destruct surrounding structures, and tendency to be malignant.^{6,7}

Histologically, papilloma can be divided into three forms including papillary or fungiform showing epithelium

proliferation with the surrounding fibrous tissue as the central part without inverted epithelium, classic inverted papilloma characterized by dominant epithelial growth below the stroma, and columnar cell papilloma which is a papilloma variant in the nasal cavity characterized by columnar cell. The recurrence and malignancy rate of columnar cell papilloma is higher than other types. Anatomically, inverted papilloma is divided into two categories, they are lateral wall papilloma and septal papilloma.⁶⁻⁸ the study aims to describe sinonasal inverted papilloma management using endoscopic approach in Zainoel Abidin General Hospital, Banda Aceh, Indonesia.

CASE DESCRIPTION

A 44-year old woman with inverted papilloma was reported. Patient complained of nasal obstruction on the right nasal cavity since two years ago which was getting worse in the last 6

months. The obstruction was described totally along with rhinorrhea. The patient also complained of intermittent occasional facial pain. There were no complaints about epistaxis and tinnitus. Patient had undergone surgery for nasal polyps at the regional hospital 4 years ago but further pathology examination has not been established. Hence, patient reported relapsing of nasal obstruction since the last 2 years.

Patient had normal vital sign. Clinical manifestation showed smooth and white-yellowish tumor mass resembling to polyp on right nasal cavity (Figure 1).

A presurgical biopsy was done with the result of inverted papilloma followed by histopathological examination. CT-Scan of paranasal sinus showed a mass filling the right nasal cavity, right maxillary sinus, and right ethmoidal sinus (Figure 2). Hyperostosis feature with the tendency to grow on the tumor, also known as "cone

shape appearance" was also found. Patient was diagnosed with inverted papilloma sinonasal with Krouse 2 classification based on clinical examination, radiological finding and preoperative endoscopy.

Intraoperative endoscopic visualization with telescope 0° on the right nasal cavity showed a mass resembling polyp with smooth surface and white-yellowish in color. The mass stalk was located on the lateral right nasal cavity and the mass also filled the right maxillary sinus, right nasal cavity, and right ethmoidal sinus (Figure 3).

Patient had been treated with mass extirpation via endoscopic approach. The tumor tissue was removed gradually using straight forceps until the tissue was completely removed and the nasal cavity was free from tumor tissue. Next, the lateral wall suspected of the tumor tissue origin was curated (Figure 4).

The removed tissue has irregular

white-reddish morphology with smooth surface which was easily ruptured and the tissue was sent to the pathology anatomy laboratory for further examination. The pathology anatomy examination of the operative tissue showed an inverted papilloma similar to the preoperative result (Figure 5).

Patient was treated with antibiotic, analgetic and anti hemorrhagic agent on the day 1 and day 2 of post-operative follow up. No bleeding was reported. Anterior nasal packing was removed on the third day with no active bleeding so that patient can be discharged.

DISCUSSION

The exact etiology of inverted papilloma remains unknown. Several theories had been proposed including allergy, chronic inflammation and carcinogen related to papilloma virus infection. The patient had

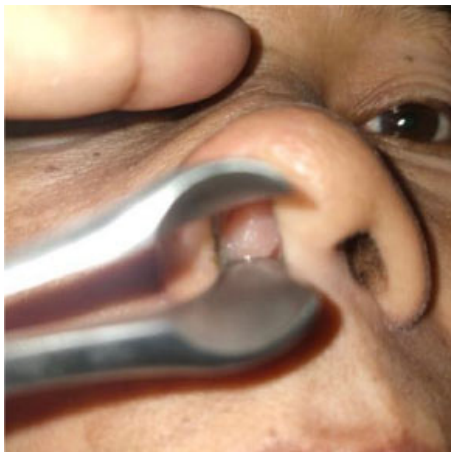

Figure 1. Rhinoscopy anterior examination found a mass on the right nasal cavity.

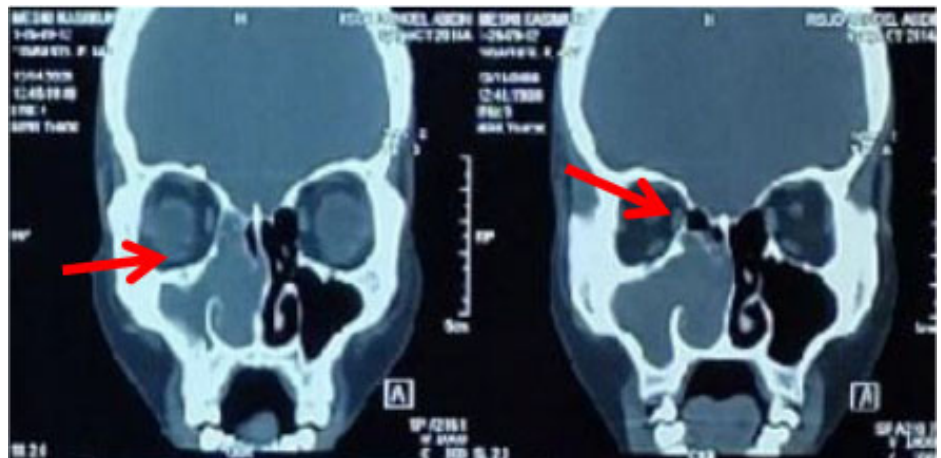


Figure 2. A mass filling the right nasal cavity, right maxillary sinus, and right ethmoidal sinus with cone shape appearance.

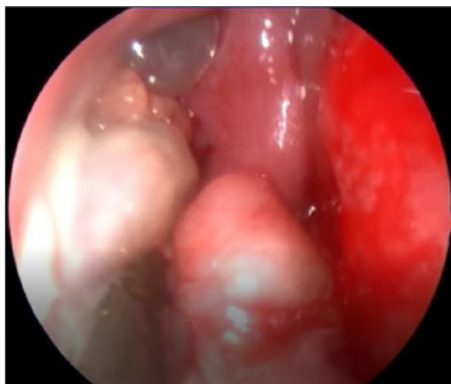


Figure 3. Mass filling right nasal cavity from endoscopic visualization.

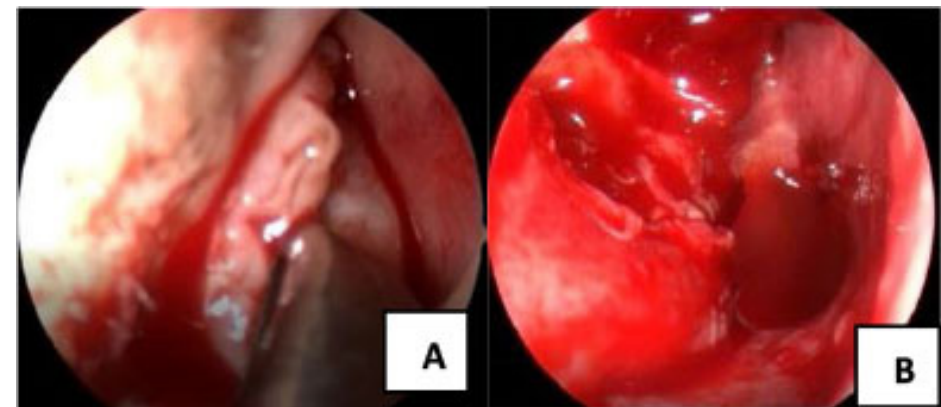


Figure 4. A. Mass extirpation via endoscopic procedures; B. Nasal Cavity condition after Mass Extirpation Procedures.

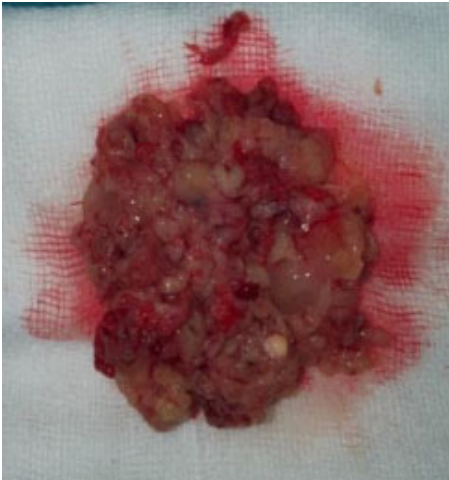

Figure 5. The appearance of mass removed from the right nasal cavity.

chronic allergic history since children with no other chronic disease history.¹⁻³

The most complained inverted papilloma manifestation is unilateral nasal obstruction. The reason was the presence of huge mass obstructing the respiratory tract. Other symptoms include rhinorrhea, epistaxis, anosmia, tinnitus, and others. This patient was referred to the specialist due to nasal obstruction since two years ago and getting worse in the last 6 months affecting individual quality of life along with persistent rhinorrhea.^{3,4,6}

Clinical examination will show tumor mass resembling unilateral nasal polyp commonly found on lateral wall of nasal cavity but also possible to be found on vestibulum, nasal septum, nasopharynx basis, sphenoidal and frontal sinus, as also lacrimal sac. Mass feature on right nasal has similar morphology with smooth and white-yellowish polyp. In the surgery, the mass stalk was found on the lateral nasal cavity while the mass filled the right maxillary sinus, right nasal cavity, and right ethmoidal sinus.^{4,6}

CT Scan revealed a soft tissue mass with increased density. The location of mass is a clue to exact diagnosis. Calcification can be found in several cases characterized with hyperostosis on the tumor origin site, also known as cone shape appearance on the right orbital basis. CT-Scan of paranasal sinus from this patient showed a mass filling the right nasal cavity, right maxillary sinus, and right ethmoidal

sinus and hyperostosis feature with the tendency to grow on the tumor which is also known as "cone shape appearance" was also found.⁹⁻¹²

Surgical approach is the treatment of choice for inverted papilloma including lateral rhinotomy, maxillectomy, degloving, and mass extirpation via endoscopy. The principle of inverted papilloma treatment is total tumor removal without residue to prevent relapse. Based on radiological findings and preoperative endoscopy, surgical treatment is determined by Krouse staging system. Patient was diagnosed with stage 2 inverted papilloma with Krouse staging. Based from the literature, inverted papilloma in Krouse 2 can be treated endoscopically by resecting the bone structures, according to the that theory the patient had been treated with mass extirpation via endoscopy approach.¹³⁻¹⁵

CONCLUSION

A 44-year old woman with inverted papilloma was reported. Inverted papilloma is a benign tumor originated from reserved cells on basal membrane. The etiology of inverted papilloma has not been fully understood. Patient complained nasal obstruction on the right nasal as the chief complaint accompanied with rhinorrhea. Diagnosis was made by biopsy of the nasal mass. The conflict of interest from this artikel is that most inverted papillomas were treated surgically based on krouse staging system. The patient was diagnosed with inverted papilloma stage 2, which had been treated by nasal cavity mass extirpation via endoscopy approach. endoscopy approach have advantages, this is minimal invasive surgery so patient will get less injury and trauma than open surgical.

DISCLOSURES

Consent for Publication

The patient has given informed consent and the patient has agreed to publish this case in a scientific journal without showing the patient's identity.

Funding

This case report funding source is by personal funding

Conflict of Interest

There is no conflict of interest in this case report.

Author Contribution

First author involved in concepting, designing and supervising the manuscript. Second author conduct the study. All authors prepare the manuscript and agree for this final version of manuscript to be submitted to this journal.

ACKNOWLEDGMENTS

I am over helmed in all humbleness and gratefulness to acknowledge my depth to all those who have helped me to put these ideas, well above the level of simplicity and into something concrete. Which helped me in doing this research and I'am thankful to them.

REFERENCES

- Jonas TR, Bailey D. Head and Neck Surgery, Otolaryngology Review 5th editionervus Lippincott Williams and Wilkins; English; 2014.
- Hanriko R, Muhartono M. Papilloma and sinonasal carcinoma. Medicine Journal. 2017;3(1):14-18.
- Wassef SN, Batra PS, Barnett S. Skull base inverted papilloma: a comprehensive review. ISRN Surg. 2012;2012:175903. doi: [10.5402/2012/175903](https://doi.org/10.5402/2012/175903).
- Thapa N. Diagnosis and Treatment of Sionasal Inverted Papilloma. Nepalese Journal of ENT Head and Neck Surgery. 2013;1:1-4.
- Lisan Q, Laccourreye O, Bonfils P. Sinonasal inverted papilloma: From diagnosis to treatment. Eur Ann Otorhinolaryngol Head Neck Dis. 2016;133(5):337-341. doi: [10.1016/j.anorl.2016.03.006](https://doi.org/10.1016/j.anorl.2016.03.006).
- Yalamanchili S. Why should disorders of the ear, nose and throat be treated by the same specialty? Can this situation persist? J Laryngol Otol. 2009 Apr;123(4):367-71. doi: [10.1017/S0022215108003769](https://doi.org/10.1017/S0022215108003769).
- Shah J. Head and Neck Surgery and Oncology Fourth Edition. New York: Elsevier; 2012.
- Snow JB. Ballengers Otorhinolaryngology Head and Neck Surgery 17 Edition. Shelton: People Medical Publishing House; 2009.
- Khandekar S, Dive A, Mishra R, Upadhyaya N. Sinonasal inverted papilloma: A case report and mini review of histopathological features. J Oral Maxillofac Pathol. 2015;19(3):405. doi: [10.4103/0973-029X.174644](https://doi.org/10.4103/0973-029X.174644).
- Shah D, Jadhav PL, Pati PS, Gupta RK, Verma G, et al. Computed Tomography Evaluation of Sinonasal Inverted Papilloma Characteristics with Origins of Tumors. International Journal of Contemporary Medicine Surgery and Radiology. 2018;4(3):C258-C262.

11. Lee DK, Chung SK, Dhong HJ, Kim HY, Kim HJ, Bok KH. Focal hyperostosis on CT of sinonasal inverted papilloma as a predictor of tumor origin. *AJNR Am J Neuroradiol.* 2007 Apr;28(4):618-21.
12. Eid M., Eissa L. Imaging of sino-nasal inverted papilloma: How can we emphasize the usefulness of the “striated pattern” sign. *Egyptian Journal of Radiology and Nuclear Medicine.* 2020;51(2):1-5.
13. Attlmayr B, Derbyshire SG, Kasbekar AV, Swift AC. Management of inverted papilloma: review. *J Laryngol Otol.* 2017;131(4):284-289.
14. Bugter O, Monserez DA, van Zijl FVWJ, Baatenburg de Jong RJ, Hardillo JA. Surgical management of inverted papilloma; a single-center analysis of 247 patients with long follow-up. *J Otolaryngol Head Neck Surg.* 2017;46(1):67.
15. Wu V, Siu J, Yip J, Lee JM. Endoscopic management of maxillary sinus inverted papilloma attachment sites to minimize disease recurrence. *J Otolaryngol Head Neck Surg.* 2018;47(1):24.



This work is licensed under a Creative Commons Attribution